Overview of Interpreting Fetal Heart Rate Tracings

FLAME LECTURE: 53

FITZMAURICE 9.9.14

Learning Objectives

- Describe approaches to assessing fetal well being
- Interpret electronic fetal monitoring
- Prerequisites
  - NONE
- See also – for applications of this lecture's concepts in various clinical settings
  - FLAME LECTURE 54: Outpatient antenatal testing
  - FLAME LECTURE 54B: The Nonstress Test (NST) and Contraction Stress Test (CST)
  - FLAME LECTURE 55: Inpatient and intrapartum fetal heart rate monitoring
  - FLAME LECTURE 70: Intermittent fetal monitoring in labor

FHR monitoring: Physiologic Rationale

- The fetal brain is incredibly sensitive to changes in blood oxygenation and pH
  - Interplay of sympathetic and parasympathetic stimulation/ tone
  - Level of fetal activity
- Identification of fetal hypoxia → opportunity to intervene
  - Decreased risk of severe metabolic acidosis leading to fetal neurologic injury or death

Antepartum Fetal Distress Cascade:

Fetal heart rate changes appear early

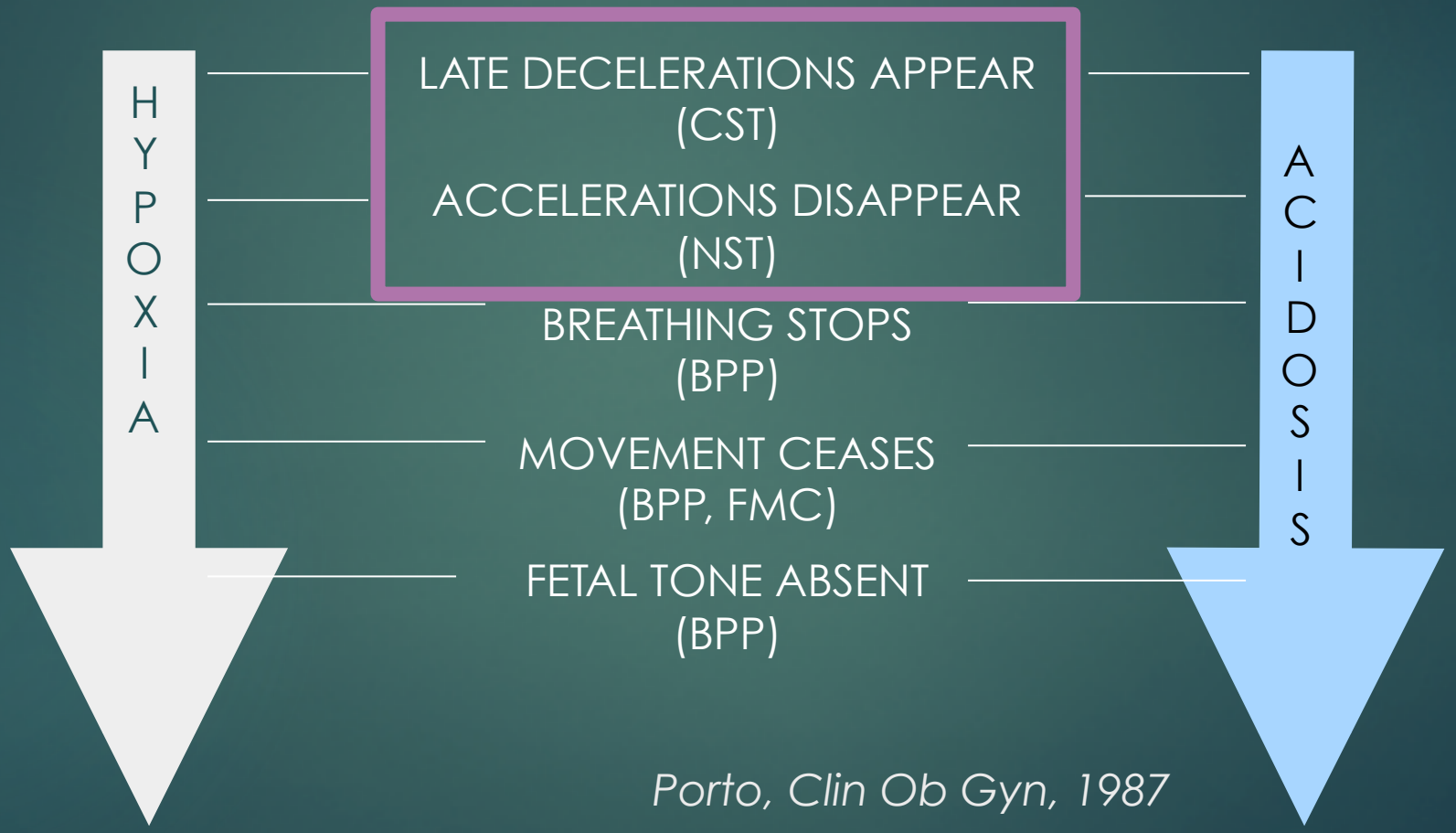

Porto, Clin Ob Gyn, 1987

Normal Fetal Heart Rate Tracing – The Basics

- Upper graph is fetal heart rate in beats per minute, each vertical box = 10 BPM;
- Lower graph is uterine activity. Significance of vertical boxes depends on type of monitor;
- Each small horizontal box is 10 seconds, each large box is one minute

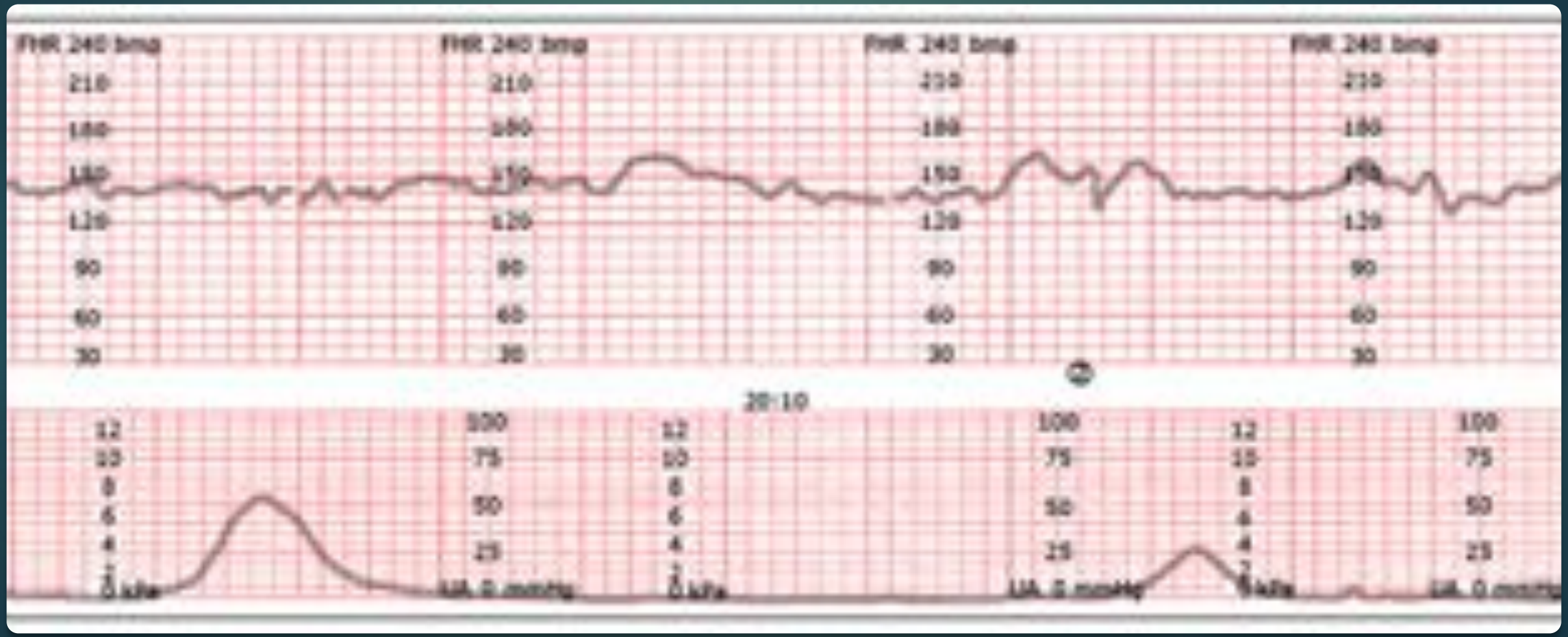

Internal vs. External Monitoring

- Fetal heart rate
  - External monitor: Doppler ultrasound
  - Internal monitor: fetal scalp electrode
    - + : Avoids loss of signal, risks of misinterpreting signal (e.g. maternal, doubling)
    - - : Requires amniotomy, small risk of scalp bleeding, hematoma, infection
- Uterine activity
  - External monitor: mechanical pressure transducer
  - Internal monitor: intrauterine pressure catheter
    - + : allows measurement of strength and precise measurement of duration of contractions, as well as baseline uterine tone
    - - : requires amniotomy, small risk of placental abruption or cord prolapse with insertion

Baseline: definition and significance

- The mean FHR rounded to increments of 5 bpm during a 10 minute segment, excluding:
  - Periodic or episodic changes
  - Periods of marked FHR variability
  - Segments of baseline that differ by more than 25 beats per minute
- The baseline must be stable for a minimum of 2 minutes in any 10-minute segment, or the baseline for that time period is indeterminate. In this case, one may refer to the prior 10-minute window for determination of baseline.
- Normal FHR baseline: FHR 110-160 beats per minute[1]
  - Parasympathetic tone becomes more dominant as neurologic maturity progresses, so usually baseline will decrease with gestational age

[1]Quoted from ACOG Practice Bulletin No. 106, Table 1

Baseline variability: definition

- Fluctuations in the baseline FHR that are irregular in amplitude and frequency
- Variability is visually quantitated as the amplitude of peak-to-trough in beats per minute.
  - Absent: amplitude range undetectable
  - Minimal: amplitude range detectable, but 5 beats per minute or fewer
  - Moderate (normal): amplitude range 6-25 beats per minute
  - Marked: amplitude range greater than 25 beats per minute[1]

Minimal to absent

Moderate

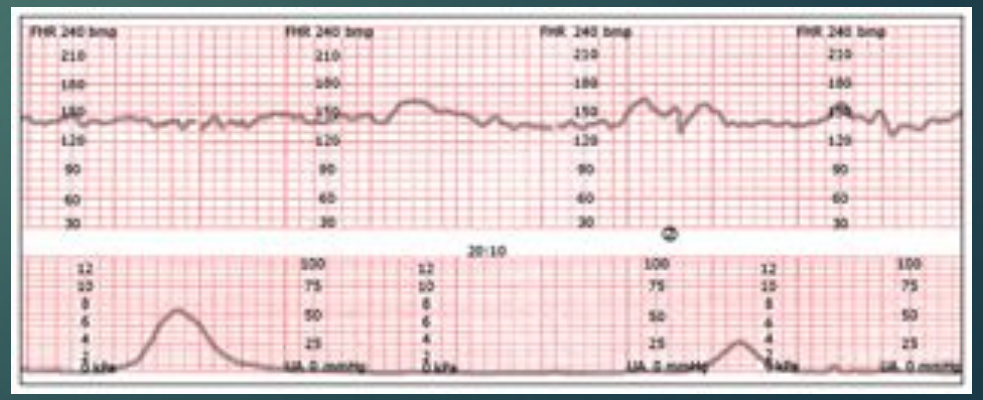

[1]Quoted from ACOG Practice Bulletin No. 106, Table 1

Baseline variability: Significance

- Differential for decreased baseline FHR variability:
  - fetal sleep cycles
  - medication response (CNS depressants, opiates, alcohol, magnesium sulfate)
  - fetal CNS anomalies (hydrocephaly/anencephaly)
  - cardiac anomalies
  - persistent fetal tachycardia
  - excessive vagal stimulation
  - prolonged or severe hypoxia
- Marked variability may also be associated with hypoxia, and is not considered reassuring

Acceleration: definition

- A visually apparent abrupt increase in FHR (onset to peak less than 30 seconds)
  - ≥ 32 weeks: an acceleration has a peak of 15 beats per minute or more above the baseline, with a duration of 15 seconds or more but less than 2 minutes from onset to return
  - < 32 weeks: an acceleration has a peak of 10 beats per minute or more above the baseline, with a duration of 10 seconds or more but less than 2 minutes from onset to return
- Prolonged acceleration lasts 2 minutes or more but less than 10 minutes in duration
- If an acceleration lasts 10 minutes or longer, it is a baseline change[1]

[1]Quoted from ACOG Practice Bulletin No. 106, Table 1

Acceleration: significance

- If accelerations are present, the fetus is very unlikely to be acidemic
- If accelerations are absent, the baby may be sleeping, and a vibroacoustic or fetal scalp stimulation may be performed. If an acceleration is elicited, the fetus is very unlikely to be acidemic.

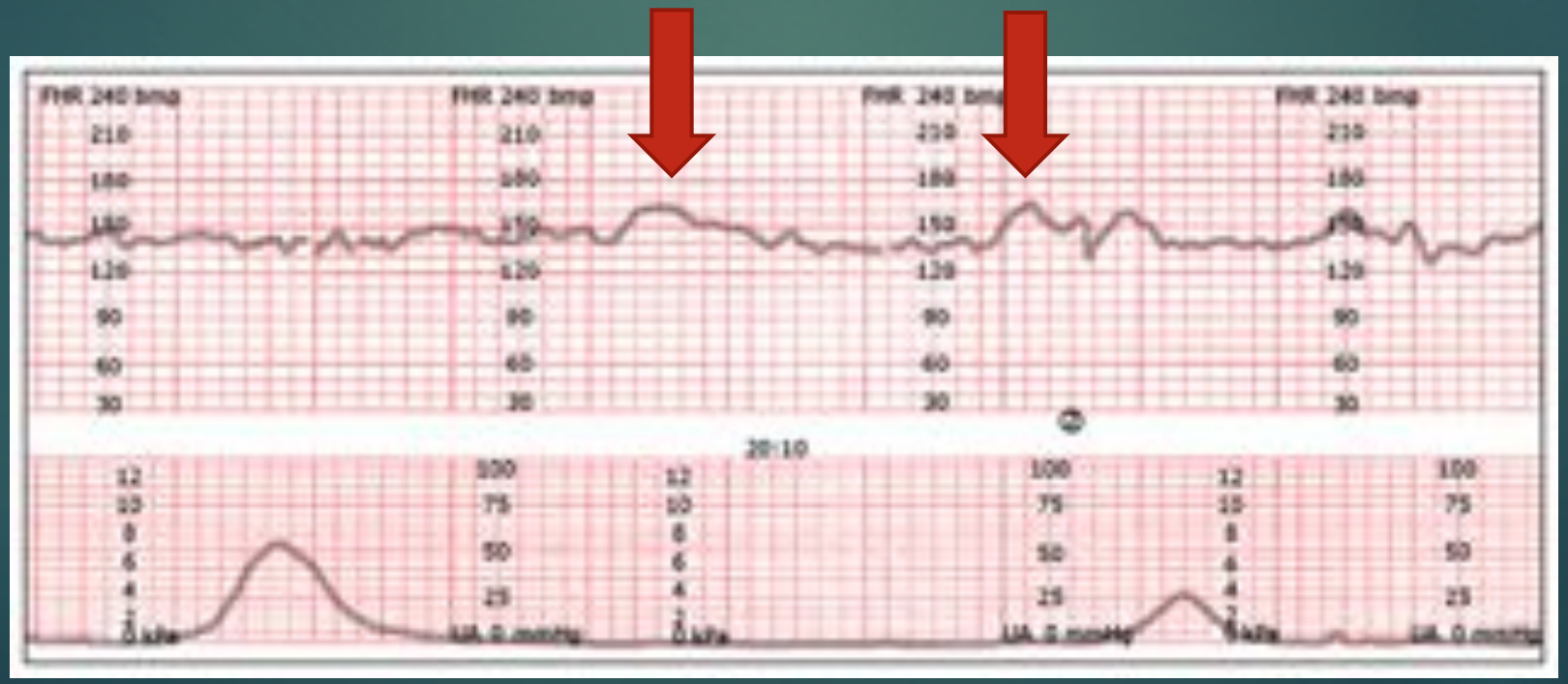

Early deceleration: definition and significance

- Visually apparent usually symmetrical gradual decrease and return of the FHR associated with a uterine contraction
- A gradual FHR decrease is defined as from the onset to the FHR nadir of 30 seconds or more
- The nadir of the deceleration occurs at the same time as the peak of the contraction
- In most cases the onset, nadir and recovery of the deceleration are coincident with the beginning, peak and ending of the contraction, respectively[1] ("mirror image")
- Etiology believed to be 2/2 vagal stimulation by fetal head compression, typically ~4-6 cm cervical dilation. NOT related to hypoxia/acidemia

[1]Quoted from ACOG Practice Bulletin No. 106, Table 1

Variable deceleration: definition

- Visually apparent abrupt decrease in FHR
- An abrupt FHR decrease is defined as from the onset of the deceleration to the beginning of the FHR nadir of less than 30 seconds
- The decrease in FHR is calculated from the onset to the nadir of the deceleration
- The decrease in FHR is 15 beats per minute or greater, lasting 15 seconds or greater, and less than 2 minutes in duration
- When variable decelerations are associated with uterine contractions, their onset, depth and duration commonly vary with successive uterine contractions[1]
- Intermittent versus repetitive decelerations: occurs with less than 50% versus greater than or equal to 50% of contractions, respectively

[1]Quoted from ACOG Practice Bulletin No. 106, Table 1

Variable deceleration: Significance

- Etiology believed to be 2/2 umbilical cord compression → increased SVR → baroreceptor mediated bradycardia
  - low amniotic fluid volume
  - short umbilical cord
  - nuchal cord
  - cord malposition or entanglement
  - prolapsed cord
  - knot in the cord
  - decreased Wharton's jelly
  - rapid descent of the fetus

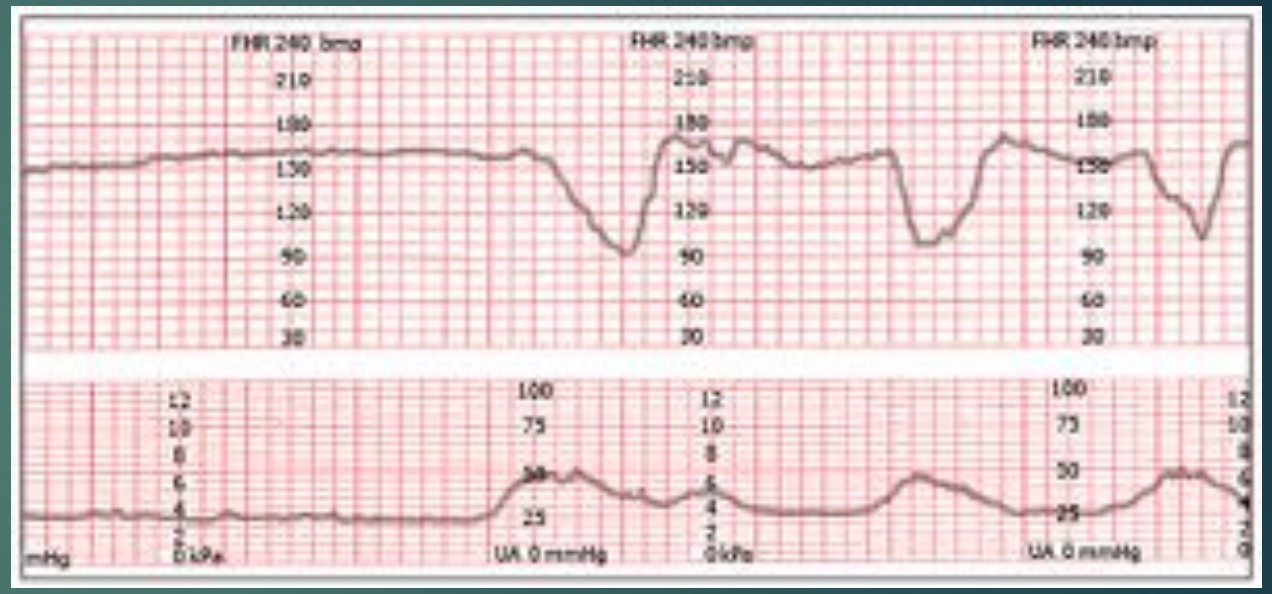

- Note there are apparent accelerations before and/or after a variable deceleration ("Shoulders")
  - Physiology: occlusion of the thin-walled umbilical vein first→ decreased venous return to heart → reflex tachycardia → compression of thick-walled arteries → increase in fetal BP → fetal baroreceptor response as above

Late deceleration: definition

- Visually apparent usually symmetric gradual decrease and return of the FHR associated with a uterine contraction
- A gradual FHR decrease is defined as from the onset to the FHR nadir of 30 seconds or more
- The deceleration is delayed in timing, with the nadir of the deceleration occurring after the peak of the contraction
- In most cases, the onset, nadir, and recovery of the deceleration occur AFTER the beginning, peak, and ending of the contraction, respectively[1]
- Intermittent versus repetitive decelerations: occurs with less than 50% versus greater than or equal to 50% of contractions, respectively

[1]Quoted from ACOG Practice Bulletin No. 106, Table 1

Late deceleration: Significance

- Etiology 2/2 uteroplacental insufficiency
  - Myometrial contraction → decreased blood flow to placenta → respiratory acidosis
  - Fetal chemoreceptor response to acidemia → decreased heart rate
- Differential diagnosis
  - Inadequate uterine relaxation
  - Placental post-maturity
  - Abruptio placentae, placental malformation
  - Chronic placental damage related to maternal disease (ex. maternal cHTN, DM, asthma)
  - Maternal hypotension (supine position, epidural, trauma, hemorrhage)
  - Pre-eclampsia
  - Cocaine/amphetamines

Other definitions

- Prolonged deceleration
  - Visually apparent decrease in FHR below the baseline
  - Decrease in FHR from the baseline that is 15 beats per minute or more, lasting 2 minutes or more but less than 10 minutes in duration
  - If a deceleration lasts 10 minutes or longer, it is a baseline change
- Sinusoidal pattern
  - Visually apparent, smooth, sine wave-like undulating pattern in FHR baseline with a cycle frequency of 3-5 per minute which persists for 20 minutes or more
  - Associated with fetal anemia

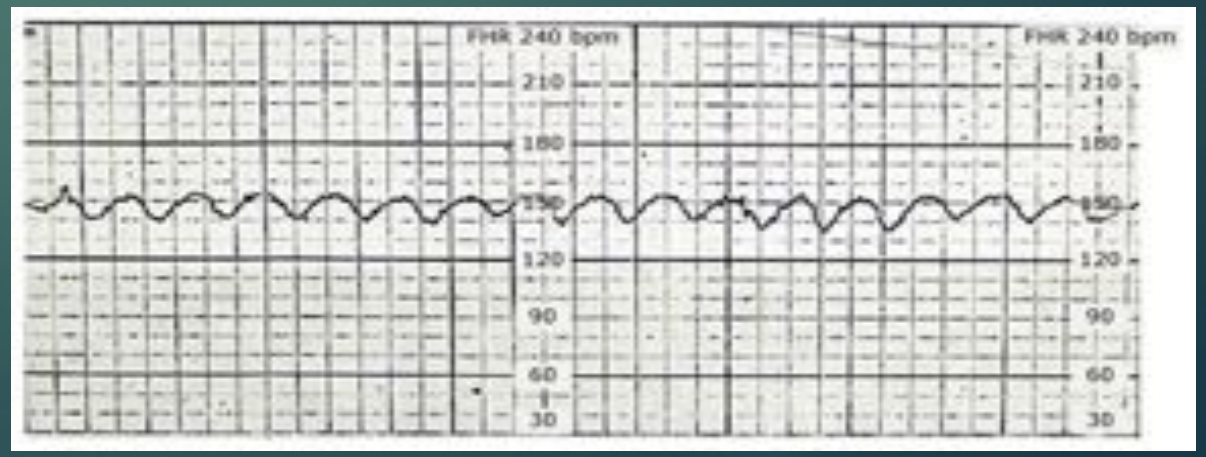

Uterine activity: definitions

- Normal: five contractions or less in 10 minutes, averaged over a 30 minute window
- Tachysystole: more than five contractions in 10 minutes, averaged over a 30 minute window
  - With associated FHR decelerations (lates or variables)
  - Without associated FHR decelerations
- In the preterm patient:
  - There is no evidence-based threshold for contraction frequency distinguishing false from early labor, but common practice considers < 4 uterine contractions per hour reassuring

IMPORTANT LINKS/REFERENCES

- ACOG PRACTICE BULLETIN 106 – Intrapartum Fetal Heart Rate Monitoring: Nomenclature, Interpretation, and General Management Principles
- UpToDate.com, Young BK - Intrapartum Fetal Heart Rate Assessment
- Please also refer to FLAME LECTURE 55 – Intrapartum fetal heart rate monitoring